

## The Use of a 0.8 mm Drill Associated with an Endodontic Guide to Access a Flatted Calcified Canal: A Case Report

Taia Maria Berto Rezende<sup>1\*</sup>, Marcelo Moreti<sup>2</sup>, Paula Guimarães Dominguete<sup>3</sup>, Poliana Amanda Silva<sup>4</sup> and Sonia Teresa de Oliveira Lara-Mendes<sup>5</sup>

<sup>1</sup>*Pós-graduação em Ciências Genômicas e Biotecnologia, Universidade Católica de Brasília, Brasília-DF, Brazil*

<sup>2</sup>*Moreti Odontologia, Brazil*

<sup>3</sup>*Pontifícia Universidade Católica de Minas Gerais, Brazil*

<sup>4</sup>*Universidade de Brasília, Brazil*

<sup>5</sup>*Universidade de Itaúna, Brazil*

**\*Corresponding Author:** Taia Maria Berto Rezende, Pós-graduação em Ciências Genômicas e Biotecnologia, Universidade Católica de Brasília, Brasília-DF, Brazil.

**Received:** March 25, 2023; **Published:** April 20, 2023

### Abstract

The purpose of the study is to describe a clinical case of endodontic treatment with guided access in the mesial canals of a calcified lower molar, using for the first time a small diameter drill (0.8 mm). The patient was referred to the clinic for localization and treatment of a calcified canal of the first left lower molar. The patient went to an emergency appointment reporting spontaneous pain, tenderness to percussion, and palpation. Radiological examination demonstrated calcification in root canals and radiolucency periapical. Because of root thinning, guided endodontics was considered the most appropriate treatment approach. However, a drill compatible with the diameter of the canal was used (0.8 mm). The use of an endodontic guide combined with a drill with a reduced diameter (0.8 mm) demonstrated greater safety, predictability, low learning curve, and less wear of the cervical and middle portions of a flattened root of a lower molar.

**Keywords:** *Endodontic Guide; Customized Drill; Flatted Calcified Canal*

### Abbreviations

CBCT: Cone Beam computer Tomography; DICOM: Digital Imaging and Communications in Medicine; STL: Standard Triangle Language

### Introduction

Partial or total root canal system calcification is characterized by mineralized tissue deposition within the dentin walls. Endodontic treatment of these teeth is a challenge for even the most experienced endodontists, and even with an operating microscope, ultrasonic tips, and long-stem burs, the failure rate remains high (62.5%). However, this procedure is needed in cases of pulp necrosis with and without periapical lesions [3,4]. Thus, considering the difficulties encountered in accessing and locating these root canals, the endodontic guided technique was introduced to facilitate the procedure execution and to reduce the risk of failure. The method includes the prepara-

tion of a three-dimensional guide, planned through the combination of tomographic images with an intraoral scan of the region. The endodontic guided technique aims to reach the remaining light of the canal in a precise and predictable way, which is unanimously confirmed in the literature [1,8,13].

Among the iatrogenic effects promoted by conventional access to calcified teeth, the excessive wear on the tooth structure reduces the mechanical resistance of the tooth element, contributing to its fracture. Thus, the greater the amount of structure preserved in the cervical region, the better the long-term prognosis of the tooth [3,5,9]. In addition, endodontic guided related literature describes the use of different drills diameters, ranging from 0.85 mm to 1.3 mm. However, the authors reported the lack of a specific drill to preserve root structure on flatted roots [6,7]. Thus, new strategies for endodontic guide techniques to flatted root canals must be developed. Therefore, this study report for the first time, a clinical case of endodontic guided performed with a reduced diameter drill (0.8 mm) in a molar, to preserve greater dentin structure and respect dental anatomy.

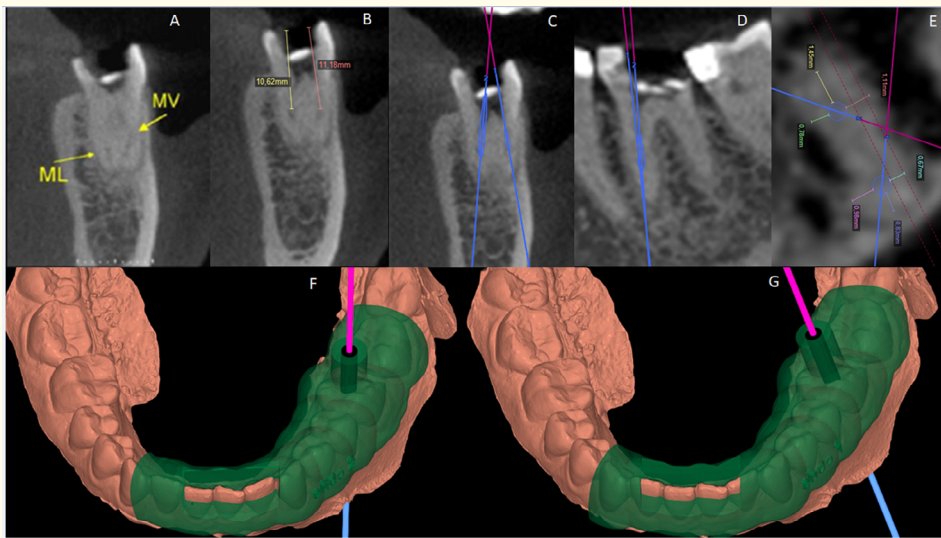
### Case Report

A 40-year-old woman was referred to the clinic for localization and treatment of a calcified canal of the first left lower molar. First, patient went to an emergency appointment reporting spontaneous pain, tenderness to percussion and palpation, besides absence of temporary restoration. Radiological examination demonstrated calcification in root canals, especially on the mesial ones and radiolucency in periapical mesial area.

In the first appointment, under anesthesia, an association of ultrasonic insertions to microscope allowed to find the distal canals. However, attempts were made to access the mesial canals without success. Calcium hydroxide (Maquira Indústria de Produtos Odontológicos SA, Maringa, Brazil) dressing was performed, and the patient receive pain relievers. Patient was asked to perform a CBCT (3D Elite, The Yoshida Dental MFG. CO. LTD, Tokyo, Japan) for diagnosis and digital planning.

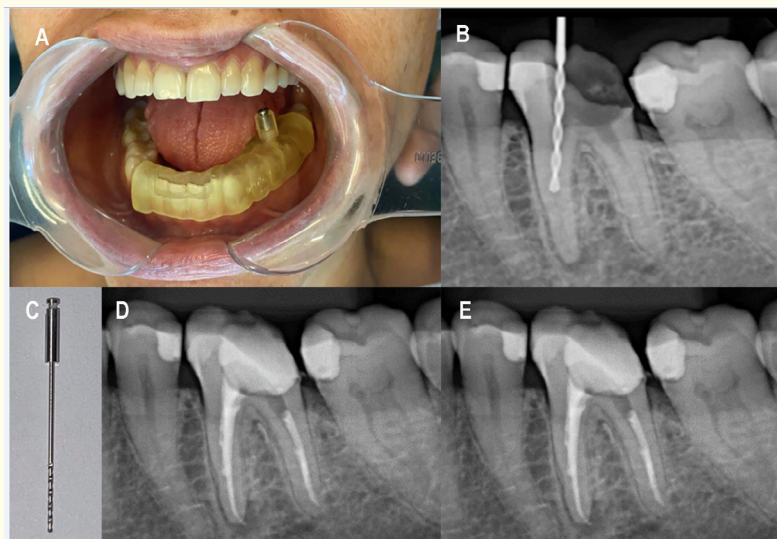
CBCT demonstrated that the lumen of the mesial canals presented only 10.62 mm in mesio-lingual canal and 11.18 mm in mesio-buccal canal (Figure 1A-1E). The patient was informed about the choices of treatment, and guided endodontics was considered as the most appropriate treatment approach. As the traditional 1.3 mm drill was not indicated for this case, a TGS metal 0.8 mm diameter drill (Radiodontica, Chapecó, Brazil) was chosen to be used (Figure 2C). Then, an intraoral scan (Cerec Omnicam AC Dentsply Sirona, Bensheim, Germany) was taken. The STL-scanner and the DICOM - CBCT files were loaded into NemoStudio virtual planning software (version 2019, Software Nemotec S.L., Madrid, Spain) and were combined surface scanning and CBCT images. First, this drill was positioned in the digital workflow software NemoStudio (version 2019, Software Nemotec S.L., Madrid, Spain) until it reached the CT scan visible lumen of the ducts (Figure 1C-1E). After that, 2 virtual models were designed since the access angle to each root canal was not parallel (Figure 1F and 1G). Templates were exported as STL files and sent to a 3D printer (MoonRay SprintRay S100, Los Angeles, USA) printed in 50 $\mu$ . After checking the inspection windows template (Figure 2A), the procedure was started without local anesthesia for the sake of sensitivity, which can indicate that a possible canal deviation could be considered. Guided access was obtained using the motor (Driller BLM 600 Plus, Carapicuíba, Brazil) at a speed of 1,200 rpm and 50 N. Care was taken to irrigate the drilling action with saline to avoid microcracks. Intraoperative radiographs were taken with different angulations each 3 mm insertion to apical direction to check the correct bur position (Figure 2B). Same procedures were performed with the second guide.

Once access was completed, local anesthesia was performed, and the tooth was isolated using a rubber dam. Subsequently, with an #08 K file (Maillefer Dentsply Boloigues, Switzerland) was used to localize the canals and the patency length was determined with an apical locator (JMorita Zx II, Tokyo, Japan). The tooth was instrumented with NiTi Prodesing S system until 25.06 (Easy Equipamentos Odontológicos, Belo Horizonte, Brazil) and irrigated with 2.5% sodium hypochlorite (Rioquímica SA, São José do Rio Preto, Brazil). After one week with calcium hydroxide (Maquira Indústria de Produtos Odontológicos SA, Maringa, Brazil), as intracanal medication, a photo-



**Figure 1:** Virtual planning of guided endodontics. A CBCT image of the first left lower molar with severe PCC on mesial canals (A-E). The model scan aligned to the 3D template and the virtual copy of the drill for ML and MB canals (F-G).

dynamic antimicrobial (P.D.T.) was performed and the canals were filled with bioceramic sealer (Bio-C Sealer Angelus, Londrina, Brazil) and gutta-percha cones (Odous De Deus, Belo Horizonte, Brazil) by hydraulic compression technique (Figure 2D and 2E).



**Figure 2:** Clinical case. The template positioned in the mouth and guided dentin drilling (A). Transoperative radiographs of guided dentin drilling (B). 0.8 mm diameter used drill (C). Final radiographs (D-E).

### Discussion

Endodontic literature is unanimity regarding the safety, precision, and predictability of the endodontic guided technique, as well as the importance of three-dimensional images for the diagnosis and treatment of calcified teeth with pulp necrosis [3,12,13]. Some authors cited the increase in radiation dose as a negative aspect of the approach. However, the number of periapical radiographs needed to perform conventional access in calcified canals totals a much greater amount of radiation [6,11]. According to Buchgreitz, *et al.* (2019), Krastl, *et al.* (2016) and Connert, *et al.* (2019), the endodontic guided technique is contraindicated in areas of root curvature, since the drill can only be introduced in straight parts of the canal [1,2,6]. Fortunately, most calcifications are found in the cervical and middle thirds, and curvatures in the apical third, not making the technique unfeasible. Another limitation mentioned initially was the execution in molars, due to restricted mouth opening [2,3,12]. However, as in the present study, Lara-Mendes, *et al.* (2018), Maia, *et al.* (2019), and Tavares, *et al.* (2020) published case reports performed on molars, demonstrating the possibility of the technique execution, once there is enough root dentin thickness [7,10,11].

Regarding dentin wear promoted using an endodontic guide, some studies mention that the diameter of the used drill could modify the original anatomy of the root canal since these are not customized to the endodontic environment measured, *in vitro*, the volume of structural wear comparing the guided technique with the conventional one [2,6,7]. The results showed significantly less loss of substance when using endodontic guide with a 0.85 mm diameter drill [2]. In contrast, Loureiro, *et al.* (2020), used a 1.3 mm diameter drill and concluded that there was a loss of dentin volume like the conventional endodontic approach, especially when dealing with mandibular incisors [9]. This fact suggests that this loss could also be significant in flatter molars, thus justifying the need for fewer caliber burs.

Finally, other aspects covered in the other studies were related to cost, treatment time, and operator experience. The additional pre-operative costs (CBCT, scanning, software, and preparation of guides) are justified by the lower risk of iatrogenic events and the greater predictability of results. In addition, the authors cited a greater number of sessions required in conventional treatment, with experienced operators and with the aid of auxiliary technologies. In contrast to the use of the endodontic guide technique where the canals are located in minutes even by inexperienced dentists [3,6,8,12,13]. As this is the first clinical case in molars, using a 0.8 mm diameter drill, it is worth emphasizing the need for additional studies, involving a larger number of patients and longer follow-up periods.

### Conclusion

The use of guides to locate canals represented a great advance in endodontics. The clinical case presented demonstrated the possibility of performing guided access in the mesial canals of a calcified lower molar, using a drill with a small diameter (0.8 mm). Thus, the use of an endodontic guide combined with a drill with a reduced diameter (0.8 mm) demonstrated greater safety, predictability, low learning curve and less wear of the cervical and middle portions of a flattened root of a lower molar.

### Bibliography

1. Buchgreitz J, *et al.* "Guided Root Canal Preparation Using Cone Beam Computed Tomography and Optical Surface Scans - an Observational Study of Pulp Space Obliteration and Drill Path Depth in 50 Patients". *International Endodontic Journal* 52.5 (2019): 559-568.
2. Connert T, *et al.* "Guided Endodontics Versus Conventional Access Cavity Preparation: A Comparative Study on Substance Loss Using 3-Dimensional-Printed Teeth". *The Journal of Endodontics* 45.3 (2019): 327-331.
3. Connert T, *et al.* "Microguided Endodontics: Accuracy of a Miniaturized Technique for Apically Extended Access Cavity Preparation in Anterior Teeth". *The Journal of Endodontics* 43.5 (2017): 787-790.
4. Cvek M, *et al.* "Failures and Healing in Endodontically Treated Non-Vital Anterior Teeth with Posttraumatically Reduced Pulpal Lumen". *Acta Odontologica Scandinavica* 40.4 (1982): 223-228.

5. Jiang Q., *et al.* "Biomechanical Properties of First Maxillary Molars with Different Endodontic Cavities: A Finite Element Analysis". *The Journal of Endodontics* 44.8 (2018): 1283-1288.
6. Krastl G., *et al.* "Guided Endodontics: A Novel Treatment Approach for Teeth with Pulp Canal Calcification and Apical Pathology". *Dental Traumatology* 32.3 (2016): 240-246.
7. Lara-Mendes STO., *et al.* "A New Approach for Minimally Invasive Access to Severely Calcified Anterior Teeth Using the Guided Endodontics Technique". *The Journal of Endodontics* 44.10 (2018): 1578-1582.
8. Lara-Mendes STO., *et al.* "Guided Endodontic Access in Maxillary Molars Using Cone-Beam Computed Tomography and Computer-Aided Design/Computer-Aided Manufacturing System: A Case Report". *The Journal of Endodontics* 44.5 (2018): 875-879.
9. Loureiro MAZ., *et al.* "Guided Endodontics: Volume of Dental Tissue Removed by Guided Access Cavity Preparation-an Ex Vivo Study". *The Journal of Endodontics* 46.12 (2020): 1907-1912.
10. Maia LM., *et al.* "Case Reports in Maxillary Posterior Teeth by Guided Endodontic Access". *The Journal of Endodontics* 45.2 (2019): 214-218.
11. Tavares WLF., *et al.* "3d Apicoectomy Guidance: Optimizing Access for Apicoectomies". *Journal of Oral and Maxillofacial Surgery* 78.3 (2020): 357 e1-57 e8.
12. Van Der Meer WJ., *et al.* "3d Computer Aided Treatment Planning in Endodontics". *Journal of Dentistry* 45 (2016): 67-72.
13. Zehnder MS., *et al.* "Guided Endodontics: Accuracy of a Novel Method for Guided Access Cavity Preparation and Root Canal Location". *International Endodontic Journal* 49.10 (2016): 966-972.

**Volume 22 Issue 5 May 2023**

**© All rights reserved by Taia Maria Berto Rezende., *et al.***